

Impaired Imagery for Upper Limbs

Leila S. Overney · Olaf Blanke

Accepted: 22 August 2008 / Published online: 18 September 2008
© Springer Science+Business Media, LLC 2008

Abstract The brain processes associated with mental imagery have long been a matter of debate. Neuroimaging and neuropsychological studies have yielded diverging evidence of mental transformation activating the right hemisphere, the left hemisphere, or both. Here, using a mirror/normal discrimination task with rotated body parts (BPs) and external objects (EOs), we describe the case of a patient who developed a selective deficit in mental imagery of such BPs due to left posterior parietal brain damage. In addition, the patient's deficit predominated for pictures of right arms (i.e., arms corresponding to the patient's imagined contralesional arm) and was further characterised by an inability to distinguish between anatomically possible and impossible arm positions. This neuropsychological deficit was corroborated by neuroimaging evidence revealing the absence of activation in the left parietal lobe for the mental rotation of body parts as shown in healthy participants. In contrast, his behavioural performance and brain activation for EOs were similar to those of healthy participants. These

data suggest that mental imagery of BPs and EOs relies on different cognitive and neural mechanisms and indicate that the left posterior parietal lobe is a necessary structure for mental transformations of human BPs.

Keywords Body parts · Electric source imaging · ERP mapping · Mental rotation

Introduction

Mental imagery refers to our ability to create and manipulate mental images, i.e., to perceive in the absence of the appropriate stimulus (Kosslyn 1994). It is of crucial importance in many of our everyday cognitive activities such as map reading or imagining the possible rearrangements of furniture in a room (Shepard and Cooper 1982). Mental rotation refers to the ability to imagine the rotation of an object in space and is one of the most common paradigms used to investigate the nature of mental transformations (Shepard 1984; Corballis 1997). Numerous reports have indeed followed the now classical mental rotation study of Shepard and Metzler (1971) demonstrating that the time required to determine whether two visual stimuli are identical or mirror reversed increases linearly with the angular discrepancy between the orientations of the two stimuli. This linear relationship between reaction time and angular difference in orientation has led investigators to suggest that subjects perform the task by mentally rotating an internal representation of one of the visual stimuli in line with the orientation of the other stimulus and then comparing the two representations for a match or mismatch. It appears then that the internal process passes through different stages of a trajectory that mimics the physical trajectory if the stimuli were to be actually rotated. Cooper

L. S. Overney (✉) · O. Blanke
Laboratory of Cognitive Neuroscience, Brain-Mind Institute,
Ecole Polytechnique Fédérale de Lausanne (EPFL), Swiss
Federal Institute of Technology, 1015 Lausanne, Switzerland
e-mail: leila.overney@epfl.ch

L. S. Overney
Macquarie Centre for Cognitive Science, Macquarie University,
2109 Sydney, NSW, Australia

L. S. Overney
Laboratory of Psychophysics, Brain-Mind Institute, Ecole
Polytechnique Fédérale de Lausanne (EPFL), Swiss Federal
Institute of Technology, 1015 Lausanne, Switzerland

O. Blanke
Department of Neurology, University Hospital, 1211 Geneva 14,
Switzerland

and Shepard (1973) used a related paradigm in which they presented single alphanumeric characters in various orientations and asked subjects whether they were in their canonical form or mirror-reversed. As in the Shepard and Metzler's task (1971), they showed that reaction times strongly increased with the angular departures of the characters from their canonical or upright orientation.

This increase in reaction time (RT) that is proportional to the orientation of the stimulus has been demonstrated for many different kinds of external objects (EOs), such as three-dimensional shapes (Shepard and Metzler 1971), alphanumeric characters (Cooper and Shepard 1973), and novel pictures of common objects (Jolicoeur 1985). However, there is a particular category of stimuli, which might lead to different patterns of results, and these are stimuli pertaining to the human body.

Mental imagery of body parts (BPs) has generally been investigated by using a laterality or handedness judgement task. Numerous authors (e.g., Parsons 1987; Cooper and Shepard 1975; Sekiyama 1982) have administered tasks in which subjects are presented with pictures of body parts in different postures and rotated angles and are asked to determine whether it is a body part that belongs to the right or left side of the body. These authors reported that in this particular situation subjects tend to spontaneously imagine their own body part in the orientation of the stimulus. During that procedure they seem to mentally simulate the kinematic properties of the physical action of their body part moving from its resting posture to that of the stimulus. Apparently, subjects tend to avoid imagining orientations that are physically awkward or impossible to adopt. Moreover, subjects report experiencing kinaesthetic sensations during this task and especially when the stimulus orientation is awkward. Using a different paradigm, we showed similar results in that anatomically possible and impossible body postures in a mental transformation task were processed differently, linked to the fact that biomechanical constraints are taken into consideration during mental transformations of BPs (Petit and Harris 2005).

Whereas the respective psychophysical properties of mental rotation of EOs and BPs have been described with a certain consistency, the exact brain processes and areas engaged in imagery of these stimuli still remain unclear and are a matter of debate and controversy. While it is generally accepted that mental rotation activates the parietal cortex, neuroimaging studies have yielded diverging evidence of mental rotation activating the right hemisphere, the left hemisphere, or both. For instance, Pegna et al. (1997), Harris et al. (2000), Harris and Miniussi (2003) have found evidence of an exclusive right hemisphere involvement in mental transformations of alphanumeric characters. Vingerhoets et al. (2001) and Alivisatos and Petrides (1997) found most activation in the left hemisphere, while an fMRI study

by Carpenter et al. (1999) demonstrated activity in both intraparietal regions for similar stimuli. In contrast, Bonda et al. (1995) showed that the mental imagery of BPs increased activity in the left hemisphere and mainly in the parietal lobe. This left parietal localisation was recently confirmed in an EP mapping study on mental transformation of BPs (Overney et al. 2005). These findings suggest that mental transformations of EOs and BPs seem to rely on different neuronal mechanisms, although most neuroimaging studies have not directly compared the mental rotation of BPs and EOs. To our knowledge, this was first investigated by Kosslyn et al. (1998) in a PET study which found that EOs (three-dimensional cubes) yielded bilateral activation in the parietal lobes, whereas BPs (hands) only led to left hemispheric activations, including the precentral gyrus, premotor area, inferior and superior parietal lobe, insula, and superior frontal cortex.

Investigations in brain-damaged patients have provided causal evidence regarding the brain areas involved in mental rotation. For instance, Farah and Hammond (1988) reported impairments in mental rotation of EOs (disoriented shapes) after damage to the posterior right hemisphere. Similar findings were provided by Ditunno and Mann (1990) who showed deficits in a mental rotation task using nonverbal two-dimensional stimuli (EOs) following lesions of the right parietal lobe. Finally, Corballis and Sergent (1988) reported a marked left-hemifield advantage for mental rotation of EOs (letters; non-verbal patterns) in a commissurotomed patient, again implying right-hemispheric specialisation. Globally, in these studies, patients showed poor accuracy and prolonged reaction times for the mental rotation of EOs.

With respect to BPs, Sirigu and Duhamel (2001) administered mental rotation tasks depicting hands as well as EOs (three-dimensional objects) to a patient with bilateral damage to the inferotemporal cortex, revealing a selective deficit for the mental rotation of EOs. Another patient showed the opposite deficit following a left fronto-temporo-parietal lesion (Rumiati et al. 2001; Tomasino et al. 2003a). The latter patient showed a selective deficit in a BP-task (mentally rotating hands in a laterality judgment task), but succeeded in an EO-task (mentally rotating three-dimensional objects). A group study in patients with unilateral brain damage confirmed these single-case studies. Tomasino et al. (2003b) observed that patients with right hemisphere damage were impaired in the mental rotation of EOs, but performed normally for BPs, whereas patients with left hemisphere damage showed the opposite pattern. Despite their importance, these studies did not measure reaction times, only carried out few trials, and were thus not able to demonstrate the presence of a "one-to-one" relation for intermediate steps of mental rotation between stimuli and patient's RTs.

Although, these data suggest that mental transformation of BPs and EOs might rely on different cognitive and neural mechanisms further neuropsychological and neuroimaging evidence seems necessary. Here we describe such evidence, in the case of a patient who developed a selective deficit in mental transformation of BPs (human arm positions) due to left posterior parietal brain damage. In addition, the patient's deficit predominated for pictures of right arms (i.e., arms corresponding to the patient's imagined contralesional arm) and was further characterised by an inability to distinguish between anatomically possible and impossible arm positions. This neuropsychological deficit was corroborated by neuroimaging evidence revealing the absence of activation in the left parietal lobe for the mental transformation of BPs as shown in healthy participants and contrasted with his performance that was similar to that of healthy participants for the mental rotation of EOs. These data suggest that mental imagery of BPs relies on different cognitive and neural mechanisms than for EOs, and indicate that the left parietal lobe is a necessary structure for mental transformations of human BPs.

Materials and Methods

Subjects

Patient

Case History, Neurological and Radiological Examination The present patient is a 65-year-old right-handed former lawyer. In March 2001, he suffered from a hemorrhagic infarction centered in the left inferior parietal lobe (Fig. 1). The lesion included the angular, supramarginal, postcentral, as well as parts of the superior parietal lobule and the posterior aspect of the superior temporal gyrus and anterior aspects of the occipital lobe. The neurological examination revealed a moderate right-sided weakness with hyperreflexia, moderate right-sided hypoaesthesia, severe right-sided loss of position sense, and global aphasia (that partially recovered, see neuropsychological examination).

In 2002, the patient presented with complex partial seizures with secondary generalisation, which were characterised initially by several sensory and complex manifestations concerning his right arm (see below) followed by right lateralised clonic movements and secondary generalisation. Seizure frequency was diminished by gabapentin (600 mg/d). EEG showed left posterior slowing. No spikes, spike-waves, sharp waves, or ictal abnormalities were observed. A follow-up MRI scan revealed subcortical atrophy adjacent to previously described brain damage, but was otherwise unchanged with respect to previous MRI investigations. In 2003, he was

hospitalised subsequently to another complex partial seizure with secondary generalisation, which the patient described as follows. While he was shopping, he suddenly felt that “his right arm had disappeared from his body”. Asked to describe this more clearly, the patient stated that he could not “feel or see his right arm” and that he was desperately “trying to find his right arm without success for several minutes”. He was brought to the emergency room where he suffered a generalised epileptic seizure associated with postictal aphasia and right-sided weakness, a few minutes after his arrival. His aphasic symptoms were increased with respect to previous control examinations. A detailed interview revealed that since 2001, he had experienced several episodes of abnormal, generally short lasting, sensations concerning his right arm. For instance, he reported that he frequently did not know in which position his right arm was and had difficulties in localising it. However, this sensation normally disappeared upon visual inspection or touching his right arm. He noted that this spontaneously occurring sensation was most prevalent at night when he woke up, or while lying awake in bed with dimmed light, although the sensation also occurred while walking or sitting in day light. Less frequently, this sensation was accompanied by the experience of not having a right arm anymore (see above). The patient did not report illusory disconnection or displacement of the right arm, illusory movement of the right arm, illusory transformations of the right arm, or a supernumerary phantom arm. No abnormal sensations were reported for other BPs.

Neuropsychological Examination During the first neuropsychological examination in March 2001, the patient was fully oriented and alert. He presented with dysarthria, and a severe global aphasia comprising all language modalities but more pronounced for oral and written expression, as well as ideomotor, ideational, and constructional apraxia. In 2002, a favourable evolution of the aphasia and apraxia was noted. Conduction aphasia with agraphia, mild ideomotor apraxia as well as mild acalculia associated with a mild dysexecutive syndrome were noted. During readmission due to seizures, more severe language difficulties were noted, with moderate global aphasia in speech and writing, phonemic paraphasias, calculation impairments, as well as mild signs of oral and ideomotor apraxia. In addition, mild autotopagnosia, mild digital agnosia, impaired left–right recognition, as well as slowness in executive tasks, and mildly impaired verbal memory were found. These resolved over the following weeks.

Prior to the present study we carried out another detailed neuropsychological examination. Regarding language, there were still mild signs of dysarthria and aphasia in speech, however his comprehension was flawless. There were no signs of prosopagnosia (Benton facial recognition

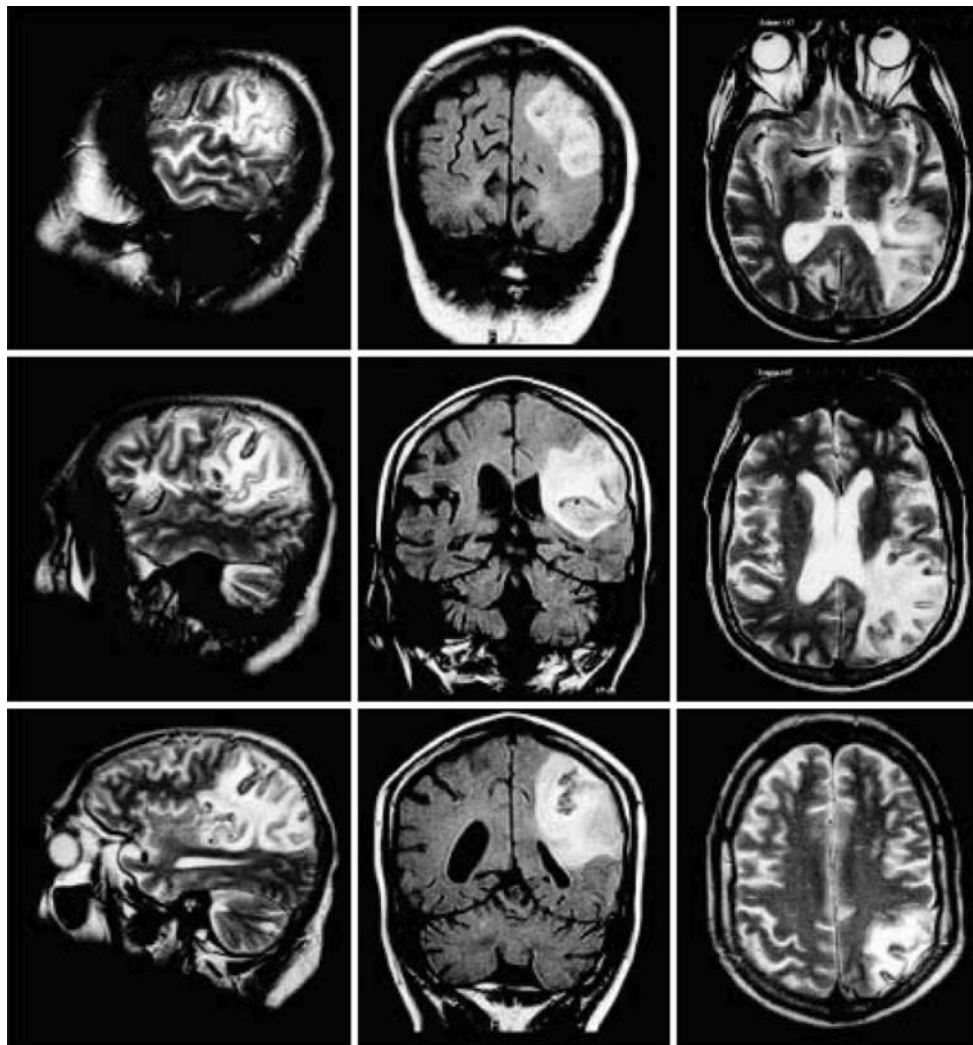


Fig. 1 Brain damage. Three different T2 weighted MRIs in the sagittal plane (*left*), coronal plane (*middle*), and transverse plane (*right*) depicting the patient's brain damage. Brain damage centered

on the angular, supramarginal, and postcentral gyri, but also included the adjacent superior parietal lobule, the posterior aspect of the superior temporal gyrus, and the anterior aspects of the occipital lobe

test, Benton et al. (1994); score = 51) or visual agnosia (Visual Object and Space Perception Battery (VOSP), Warrington and James 1991; scores in all 8 subtests were above the 5% cut-off scores). Visual recognition of superimposed figures and illusory drawings was perfect. There were no signs of autotopagnosia; the indication of BPs on his own body and on the examiner's body on verbal command was perfect (16/16). In finger agnosia assessment, which involved tactile stimulation and a verbal response without visual control, the patient's performance was flawless for the left hand. Right hand testing yielded few errors (3/10). In the Culver test (Culver 1969) showing hands and feet with right or left orientation his score was 16/20, which is within the normal range of performance (mean = 17.16; SD = 2.89). In a mental rotation task involving several EOs (Hauert and Sevino 1996), he made few errors (10/84), but this was within the normal range.

Control Participants

The behavioural data of the patient were compared to an age-matched control group. Seven healthy males matched for age and education participated in the study (mean age: 57 years; range: 49–64 years). For ERP analysis, data were compared to a control group, the results of which were reported in a previous study (Overney et al. 2005). The ERP control group was composed of eleven healthy university-level subjects (7 males, 4 females; mean age: 28 years; range: 24–32 years). Handedness was evaluated using the Oldfield-Edinburgh questionnaire (Oldfield 1971). All participants were considered right-handed as they scored between +0.8 and +1 on that scale. All had normal or corrected-to-normal vision, were not under any medication and had no history of neurologic or psychiatric dysfunctions. Participants and the patient gave their written

informed consent after having received instructions concerning the experimental procedure. This research was approved by the ethical committee of Geneva University Hospital.

Stimuli

Two different categories of stimuli were used for the experimental paradigms. For the task (see details below) with rotated BPs, we used a stimulus that showed the upper part of a human figure seen from the back with her right or left forearm in different orientations (Fig. 2a). For the task of EOs, the stimuli comprised the letters F (Fig. 2b), R (Fig. 2c), and an arrow (Fig. 2d). All pictures were taken from the Premium Image Collection of Hemera Technologies Inc. (1997–2000), transformed with a picture-editing software (Corel Photo-Paint) and scaled to the same proportions.

Human Body Parts

In the BP-task there were two main (but separate) arm rotations: one of the right arm and one of the left. Two versions of each of these pictures (woman with right arm in rotation, and woman with left arm in rotation) were created. There was one version in which the rotated segment and the rest of the body matched (e.g., the right forearm

attached to the right upper arm; Fig. 2a, line M; or the left forearm attached to the left upper arm). In the other version, the opposite limb was attached to the body (e.g., the left forearm was attached to the right upper arm, Fig. 2a, line O; or the right forearm was attached to the left upper arm). This was done by creating a mirror image of the original picture of the BP. For each picture, the orientation of the forearm was varied, with the rest of the body fixed in a vertical position. The forearm was presented in seven different orientations, ranging from 0° (vertical, canonical orientation) to 180° (upside-down) in 30° increments. This implies that four angles (0°, 30°, 60°, 90°) corresponded to the possible range of movement for the forearm and that three of them (120°, 150°, 180°) corresponded to anatomically impossible orientations. Thus, there were 14 stimulus conditions (2 stimulus versions: “matching” and “opposite” × 7 orientations) for each picture (woman with right arm in rotation, and woman with left arm in rotation). It is important to note here that although the present task was the same as that reported in Overney et al. (2005), we added one stimulus condition (the left forearm’s rotation) here in the behavioural task in order to produce imagined movements of both forearms (since the patient suffered from right hemiparesis). However, only the right forearm’s data were analysed in the ERP since they were compared to previously recorded data which had only used the right forearm stimulus.

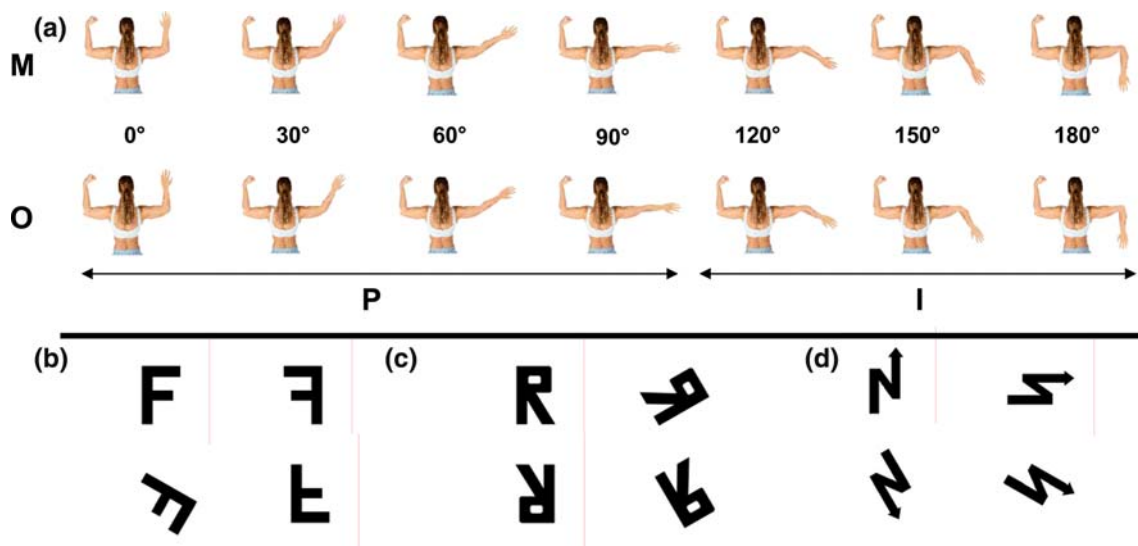


Fig. 2 Stimuli for the mental rotation task with BPs and EOs. (a) Represents the BP stimuli and (b–d) the EO stimuli. (a) The seven orientations (0° to 180°) of the BPs are shown for both the Matching (M) (the forearm matches the side of the body it is attached to) and the Opposite (O) (a left forearm and hand attached to the right upper arm) conditions. Orientations from 0° to 90° represent Possible Postures (P) whereas orientations from 120° to 180° represent Impossible Postures (I). The subjects’ task was to decide whether

the body part was the matching or opposite one. (b–d) For the EOs (b, letter F; c, letter R; d, arrow), we used the usual, canonical view and its mirror image for each EO. All EOs were rotated in seven orientations as done for the BP stimuli. The arrow was given an arbitrary correct view, which is the top left one in (d). The subjects’ task was to decide whether the EO was shown in correct view or mirror reversed

External Objects

The stimuli of the EO-task were adapted to the BP-task with respect to the axis of rotation and orientation. In addition, the two versions of the EO-task consisted of a correct (or canonical) view and the mirror-reversed view (see Fig. 2b, c, d) corresponding to the matching and opposite conditions of the BP-task, respectively. The arrow was given an arbitrary “correct” view (with the triangle on the right hand side of the figure and facing upwards) in order for the subjects to be able to decide clearly whether the presented stimulus was “correct” or “reversed” since the arrow did not have a clear canonical view as the other EOs. The EOs were rotated in the same 7 orientations as the forearm and there were also 14 stimulus conditions (2 stimulus versions: “correct” and “reversed” \times 7 orientations).

Procedure

Each stimulus was presented in a separate block, comprising 140 trials (10 “matching” and 10 “opposite” trials for each of the 7 orientations) in random order. For example, in the case of the BP, the 10 “matching” trials consisted of 10 repetitions of a right hand on a right arm (Fig. 2a, line M) and the 10 “opposite” trials were 10 repetitions of a left hand on a right arm (Fig. 2a, line O). All subjects (controls and patient) completed a total of 560 trials, with a short break of approximately 5 min (up to 10 min for the patient) between each block of 140 trials. Subjects sat in front of a 17" computer screen (refresh rate 75 Hz) placed at a distance of 120 cm. Following electrode placement subjects were given instructions concerning the task, along with an illustration of “matching” and “opposite” body or external stimuli in various orientations. At the beginning of each block they had 10 practice trials pertaining to the relevant stimulus. Subjects were instructed to avoid tilting their head, to keep their gaze on the fixation point throughout the task and were asked to answer as quickly as possible whether or not the rotated stimulus was the matching (i.e., anatomically correct for the BP, or correct EO), or if it was the opposite one (i.e., anatomically impossible limb, or mirror-reversed EO). For the control group, half the subjects gave their response by pressing one key with their right index finger if the BP was the matching one and a second key with their middle finger otherwise. The other half of the group responded in the reverse manner. As for the patient, the response was given by pressing one key with his left index finger if the stimulus was the matching one and a second key with his left middle finger otherwise (due to the patient’s mild right weakness he was instructed to respond with his left hand). Each trial consisted of a stimulus presented for 360 ms at the centre

of the screen, followed by a fixation cross which remained visible until a response was given.

EEG Acquisition and Analysis

EEG data were acquired with a Geodesics Netamps system (Electrical Geodesics, Inc., USA) from 123 scalp electrodes (impedances <50 k Ω ; vertex reference; 500 Hz digitization; band pass filtered 0.1–200 Hz).

We used a topographic analysis method as described by Murray et al. (2008). Epochs of EEG from 0 ms to 700 ms post-stimulus onset were averaged for each of the 14 stimulus conditions and for each control subject to calculate the event-related potential (ERP). Only trials leading to correct responses were included. For the patient we could only average EEG epochs from 0 ms to 600 ms post-stimulus onset due to his many uncontrolled eye blinks. These epochs were averaged for each of the 14 conditions and for each of the four stimuli to calculate the event-related potential (ERP). For the patient we also had to include correct and incorrect trials since many trials had to be discarded due to artefacts and high error rates in several conditions. Off-line processing of the scalp data consisted of visual rejection of trials contaminated by artefacts. ERPs were reduced to a 111-channel montage by eliminating the most inferior line of electrodes (Blanke et al. 2005; Overney et al. 2005; Petit et al. 2006). For each task (BP, EO), we collapsed the 14 stimulus conditions for each of the four stimuli into four grand-mean series. The “MP” series corresponds to the Matching (or correct) stimulus in the Possible orientations (0° to 90°), the “MI” series corresponds to the Matching stimulus in the Impossible orientations (120° to 180°), the “OP” series corresponds to the Opposite (or reversed) stimulus in the Possible orientations (0° to 90°), and the “OI” series corresponds to the Opposite stimulus in the Impossible orientations (120° to 180°). This was done for control subjects and the patient. Obviously, in the case of EO’s the labels Possible and Impossible had no meaning, but simply refer to the same rotation ranges described above.

In the next step of analysis, a spatial cluster analysis (Pascual-Marqui et al. 1995) identified the most dominant scalp topographies appearing in the group-averaged ERPs from each grand-mean series (MP, MI, OP, OI) over time summarising the ERP data by a limited number of scalp configurations (Lehmann et al. 1986; Michel et al. 2001). The optimal number of segmentation maps that explains the whole data set is determined by a modified cross validation criterion (Pascual-Marqui et al. 1995). The appearance of these segmentation maps in the group-averaged data was statistically verified in the ERPs of the individual healthy subjects. For each time point of the individual subject’s ERP, the scalp topography was

compared to all segmentation maps and was labelled according to the one with which it best correlated revealing if a given ERP is better described by one segmentation map vs. another. That is, from this fitting procedure, we determined the total amount of time a given map was observed for a given condition across subjects. The patient's ERP data were compared to the segmentation maps of the healthy control subjects (group-averaged data) and were labelled in the same fashion. We also determined for the patient the duration of each map for a given condition.

The final step of analysis consisted of estimating the localization of the brain areas activated during each segment, using a 3-dimensional distributed linear inverse solution (LAURA; Grave de Peralta et al. 2001, 2004; Michel et al. 2004). This solution incorporates the known biophysical laws regarding the spatial attenuation of the source strength in terms of a local autoregressive average with coefficients depending on the distances between solution points. The lead field applied to this model was calculated on a realistic head model with 4024 solution points, equally distributed in the grey matter of the average brain provided by the Montreal Neurological Institute (MNI, Montreal, Canada). Several simulation and application studies showed that this localization procedure reveals meaningful estimates of the intracerebral sources (e.g. Itier and Taylor 2004; Michel et al. 2001; Murray

et al. 2004; Schnider 2003; Blanke et al. 2005; Arzy et al. 2006).

Results

Behavioural Results

The mean reaction times (RTs) for the correct responses and the error percentages for the BPs are shown in Fig. 3 and are plotted separately for the control subjects (a, c) and the patient (b, d).

BP-task

Reaction Times The patient's RTs (mean = 3,125 ± 1,598 ms) were significantly longer than those of the control subjects (847 ± 491 ms).

The RTs for the correct trials were analysed using a 2×7 repeated measures ANOVA with Match (matching BP versus opposite BP) and Orientation (0° , 30° , 60° , 90° , 120° , 150° , 180°) as within-subject factors. In the case of the control subjects, it revealed a main effect of Match ($F(1, 6) = 6.06$, $P < .05$) for the right arm, with shorter RTs for the matching BP than for the opposite one, however, no main effect of Match was observed for the left arm

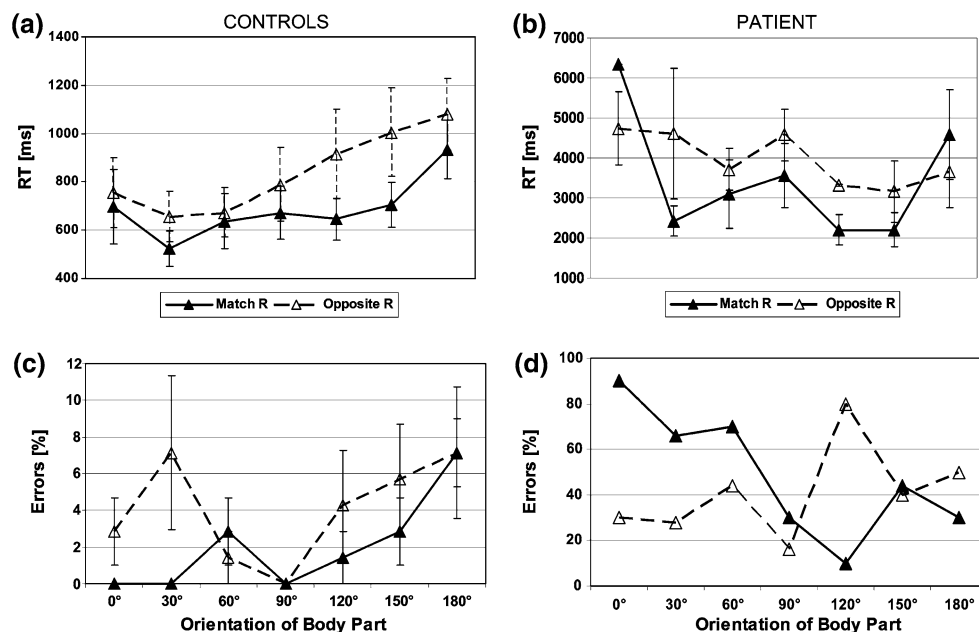


Fig. 3 Performance of control subjects and patient in the BP task shown for the right hand. The mean reaction times for the control subjects (a) and for the patient (b) are shown as well as the mean percent error rates for the control subjects (c) and the patient (d). Mean reaction times and mean percent error rates are depicted as a function of orientation (0° – 180°) and are plotted separately for

Matching Right arm (black triangle, full lines) and Opposite Right arm (empty triangle, dashed lines) configurations of the BPs. Angles greater than 90° represent impossible orientations. Whereas control subjects showed a mental rotation function the patient did not increase his reaction times and error rates with increasing angles of rotation (see text for further explanation). Error bars indicate standard errors

($F(1, 6) = 0.0002, P = .98$). There was a main effect of Orientation for the right arm ($F(6, 36) = 8.01, P < .001$) and the left arm ($F(6, 36) = 4.31, P < .005$), with RTs increasing gradually as the BP was rotated further from the upright, indicating the presence of the expected mental rotation function (see Fig. 3a). No significant Match \times Orientation interaction was obtained for either arm ($F(6, 36) = 1.48, P = .21$ for the right, and $F(6, 36) = .53, P = .77$ for the left arm).

Interestingly, the patient showed quite a different pattern of performance. As can be seen in Fig. 3b, the typical mental rotation function was not present for the patient's RTs in the BP-task, contrasting with the data from the control subjects (see Fig. 3a). For the patient, the 2×7 repeated measures ANOVA with Match and Orientation as within-subject factors did not reveal significant effects (Match: $F(1, 9) = 2.18, P = .17$; Orientation: $F(6, 54) = 2.02, P = .078$; Interaction: $F(6, 54) = .47, P = .82$ for the right arm and Match: $F(1, 9) = .97, P = .35$; Orientation: $F(6, 54) = .56, P = .76$; Interaction: $F(6, 54) = 1.28, P = .28$ for the left). Thus, the patient's RTs did not show a mental rotation function and did not differentiate between possible and impossible body postures as did the RTs of the control group. In order to confirm these results, we also conducted a 2×2 ANOVA with Match (Matching vs. Opposite Arm) and Posture (Possible vs. Impossible) as within-subject factors in control subjects and the patient to compare possible and impossible arm postures more directly (Petit and Harris 2005; Overney et al. 2005). The ANOVA carried out on the control subjects' data for the right hand showed a main effect of Match ($F(1, 20) = 13.14, P < .01$) and Posture ($F(1, 20) = 18.93, P < .001$) with a significant Match \times Posture interaction ($F(1, 20) = 5.25, P < .05$). Thus, stimuli depicting impossible body positions and postures (i.e., MI, OP and OI conditions) led to greater RTs than stimuli depicting possible body positions (MP condition). The same ANOVA carried out for the left hand showed no main effect of Match ($F(1, 20) = .00006, P = .99$), but revealed a main effect of Posture ($F(1, 20) = 7.35, P < .05$), with longer RTs for impossible body postures. No significant interaction was observed ($F(1, 20) = .47, P = .49$). Thus, for the control subjects, impossible body postures induced longer RTs than possible ones in both right and left arms. This was not the case for the patient and statistical analysis showed no main effects for the right arm (Match, $F(1, 9) = .24, P = .63$; Posture, $F(1, 9) = .86, P = .37$) and no interaction ($F(1, 9) = .02, P = .89$), nor for the left one (Match: $F(1, 9) = .06, P = .80$; Posture: $F(1, 9) = 1.46, P = .26$), interaction: ($F(1, 9) = 1.48, P = .25$). Thus, whereas healthy subjects need more time to mentally rotate impossible and non-matching arm positions, these effects were not found for the present patient.

Error Rates The patient's error rates ($55 \pm 25.3\%$) were significantly higher than those of the control subjects ($6.3\% \pm 10.6\%$). The 2×7 repeated measures ANOVA for the control subjects showed no significant main effect of Match ($F(1, 6) = 2.75, P = .14$ for the right arm and $F(1, 6) = 1.74, P = .23$ for the left arm). However, it revealed a main effect of Orientation for the right arm ($F(6, 36) = 2.53, P < .05$), with error rates gradually increasing with the angle of rotation, but not for the left arm ($F(6, 36) = 1.8, P = .12$). No significant interaction was observed for the right arm ($F(6, 36) = .80, P = .57$), nor for the left ($F(6, 36) = .98, P = .45$).

The analysis of the patient's error rates by a multidimensional chi-square analysis (Winer et al. 1991) for the right hand revealed no significant main effects (Match ($\chi^2(1) = 3.32, P = .07$); Orientation ($\chi^2(6) = 3.69, P = .72$)). Yet, a significant interaction between Match and Orientation ($\chi^2(6) = 27.36, P < .001$) was found for the patient, indicating that in the case of the matching arm fewer error rates were found for the possible orientations than for the impossible orientations. This trend was reversed for the opposite arm condition. The analysis of the patient's error rates for the left hand showed no main effects nor interaction (Match ($\chi^2(1) = .01, P = .90$); Orientation ($\chi^2(6) = 9.89, P = .13$); interaction ($\chi^2(6) = 6.29, P = .39$)).

Contralesional Versus Ipsilesional Arm Positions As a final analysis, we were interested in comparing the patient's performance for stimuli showing the rotation of a right arm (corresponding to the patient's imagined contralesional arm) with stimuli showing the rotation of a left arm (corresponding to the patient's imagined ipsilesional arm). The results revealed that RTs were longer whenever the patient was carrying out the BP-task with stimuli depicting his imagined contralesional arm. Mean RTs for the right arm were $3,125 (\pm 1,598)$ ms and for the left arm were $2,478 (\pm 1,431)$ ms. This difference was found to be significant ($t_{(99)} = 3.07, P < .01$). In contrast to RTs, error rates between the contralesional ($55 \pm 25.3\%$) and ipsilesional ($62 \pm 17.3\%$) arms did not differ significantly ($\chi^2(1) = 1.79, P = .18$).

A similar analysis carried out on the control subjects' data revealed that mean RTs and error rates were significantly different ($t_{(97)} = -4.37, P < .001$ for RTs and $t_{(97)} = -4.99, P < .001$ for error rates) with an advantage of the right arm ($762 (\pm 359)$ ms; $3 (\pm 5.9\%)$ error rate) over the left one ($932 (\pm 583)$ ms; $9.5 (13\%)$ error rate). Thus, control subjects performed the task more easily when the right hand (corresponding to their dominant hand) was presented compared to the left, whereas the patient showed the opposite pattern.

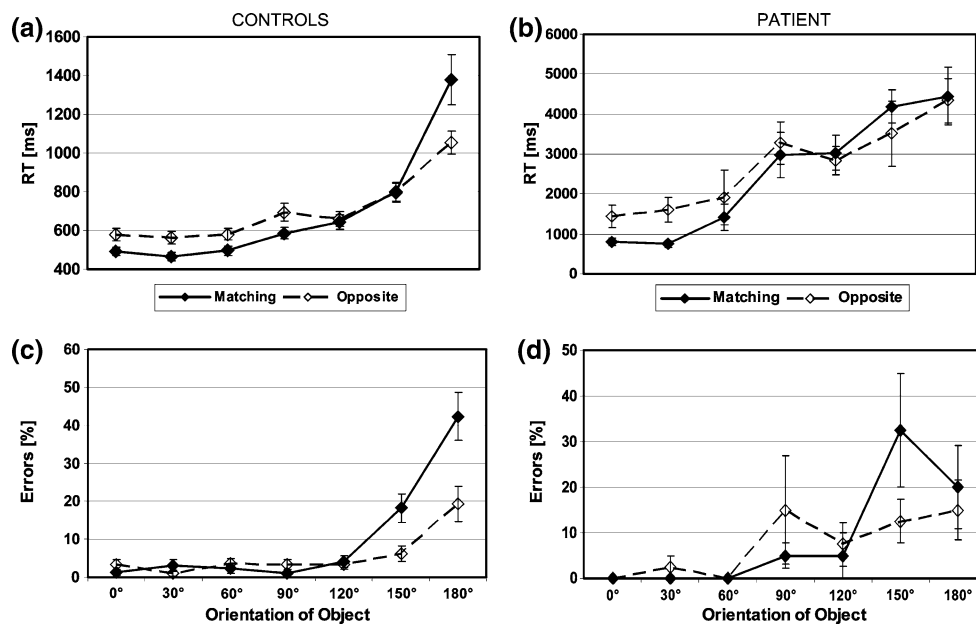


Fig. 4 Performance of control subjects and patient in the EO task. The mean reaction times for the control subjects (a) and for the patient (b) are shown as well as the mean percent error rates for the control subjects (c) and the patient (d). Mean reaction times and mean percent error rates are depicted as a function of orientation (0°–180°) and are plotted separately for Matching (correct; full squares; full

lines) and Opposite (mirror reversed; empty squares; dashed lines) configurations of the EOs. Note that control subjects and patient showed a mental rotation function (increasing reaction times and error rates for increasing angles of rotation). Error bars indicate standard errors

EO-task

The mean RTs for the correct responses and the error percentages for the EOs are shown in Fig. 4 and are plotted separately for the control subjects (a, c) and the patient (b, d). As the data for the different EOs (i.e., letters and arrows) did not differ, they were collapsed for analysis.

Reaction Times The mean RTs for the patient (mean = 1,710 ± 963 ms) were significantly prolonged compared to the control subjects (657 ± 282 ms), although, contrary to the BP-task, the patient's pattern of performance was qualitatively similar to the controls. Moreover, the comparison of the patient's mean RTs in the BP and EO tasks revealed a significant difference ($t_{(140)} = 10.89$, $P < .001$).

In the control subjects, a 2 × 7 repeated measures ANOVA (with Match (standard EOs vs. mirror-reversed EOs) and Orientation (0°, 30°, 60°, 90°, 120°, 150°, 180°) as within-subject factors) showed no main effect for Match ($F(1, 25) = 1.38$, $P = .25$), but revealed a main effect for Orientation ($F(6, 150) = 53.47$, $P < .001$). This indicates that a mental rotation function was present, with RTs increasing monotonically with the angular departure from 0° (Fig. 4a). Moreover, a significant Match × Orientation interaction was observed ($F(6, 150) = 3.24$, $P < .01$), with slightly higher RTs for mirror-reversed than standard EOs

for the smaller rotation angles and a reversed pattern for the greater rotation angles.

Inspection of Fig. 4b reveals a mental rotation function also in the patient's RTs. The 2 × 7 repeated measures ANOVA with Match (standard EOs vs. mirror-reversed EOs) and Orientation (0°, 30°, 60°, 90°, 120°, 150°, 180°) as within-subject factors revealed a main effect of Orientation ($F(6, 66) = 16.74$, $P < .001$), with RTs increasing linearly with the angle of rotation. Similar to the Controls' results, it also revealed a significant Match × Orientation interaction ($F(6, 66) = 3.16$, $P < .01$), with longer RTs for the mirror-reversed EOs than for the standard EOs in the smaller orientations but shorter RTs for the mirror-reversed EOs than for the standard EOs in the larger orientations. No main effect of Match was obtained ($F(1, 11) = 3.8$, $P = .08$).

Error Rates The patient's error rates (8.21 ± 9.7%) were similar those of the control subjects (8 ± 19%). Inspection of Fig. 4d shows that the pattern of the patient's performance in the EO-task was similar to that of the control group. Moreover, the comparison of the patient's mean errors in the BP and EO tasks revealed a significant difference ($\chi^2(1) = 255.24$, $P < .001$).

In the control subjects, the same 2 × 7 repeated measures ANOVA with Match and Orientation as within-subject factors was carried out on error rates. It revealed a

main effect of Match ($F(1, 38) = 12.83, P < .001$), with higher error rates for the standard EOs. There was also a main effect of Orientation ($F(6, 228) = 28.77, P < .001$), with errors increasing as a function of angular disparity. Finally, a significant Match \times Orientation interaction ($F(6, 228) = 10.52, P < .001$) was shown, with similar error rates for normal and reversed views in the smaller angles of rotation but higher error rates for the normal views in the larger angles of rotation.

For the patient, similar to the effects observed for RTs, a mental rotation function (i.e., an increase of errors proportional to the angle of rotation) was observed. This was confirmed by a multidimensional chi-square analysis (Winer et al. 1991), which revealed a significant effect of Orientation ($\chi^2(6) = 21.04, P < .01$). There was no effect of Match ($\chi^2(1) = .77, P = .38$). However, a significant Match \times Orientation interaction ($\chi^2(6) = 19.39, P < .01$) was observed, indicating that similar error rates were found for the smaller angles of rotation for normal and reversed views, whereas there were more errors for the normal views in the larger angles of rotation. This was the very same interaction as shown in the control subjects.

Electrophysiological Results

BP-task

Healthy Participants As reported previously (Overney et al. 2005), ERP analysis revealed 13 maps for the four grand-mean ERPs of the conditions MP, MI, OP, OI. One map (Map R_{BP}) that appeared between 310 and 380 ms after stimulus onset (indicated in dark red in Fig. 5a) was particularly interesting as its duration was longer in conditions MI and OI and thus prolonged for conditions with greater rotation angles and impossible limb positions. A repeated measures ANOVA with Condition (MP, MI, OP, and OI) and duration of Map R_{BP} as within-subject factors for the 310–380 ms time window revealed a significant Condition \times Map interaction ($F(3, 30) = 3.72, P < .05$), indicating that the duration of Map R_{BP} increased according to the angle of rotation (MI and OI are more rotated than MP and OP, see Fig. 5a) or according to impossible arm positions. In order to test whether the duration of Map R_{BP} rather reflected greater rotation angles or impossible arm position, we looked for its presence in the individual ERPs of each of the 14 angles (7 angles for the Matching stimulus and 7 for the Opposite one). This is illustrated in Fig. 5e for the control subjects (dark red line). The duration of Map R_{BP} is shown to increase linearly with the angle of rotation, which suggests that Map R_{BP} is rather related to processes of mental rotation than the processing of impossible arm positions. This was confirmed by the presence of a linear trend in the duration of Map R_{BP} as a

function of Orientation (correlation coefficient $r^2 = .78$; Fig. 5e). As reported previously (Overney et al. 2005) a linear inverse solution localised Map R_{BP} in the left hemisphere including the left parietal cortex (in the intra-parietal sulcus region), the left lateral extrastriate cortex (at the temporo-occipital junction), and the left occipital cortex (Fig. 6a).

BP-task

Patient As Map R_{BP} was linked to the mental rotation for BPs (Overney et al. 2005) and as the patient's behaviour showed that he processed the BP stimuli differently, we examined the appearance of Map R_{BP} in the patient's ERPs. As shown in Fig. 5b, Map R_{BP} was absent in both conditions with small angles of rotation (MP, OP) as well as condition OI and thus only present in the condition with large possible angles of rotation (MI; from 424 to 460 ms, indicated in light red in Fig. 5b). If compared to the healthy subjects, we found that the duration of Map R_{BP} was significantly shorter (outside the 95% confidence interval) in the patient (mean = 9 ms; range = 0–36 ms) than in the control subjects (mean = 45 ± 13 ms (SD); compare Fig. 5a, b). Importantly, Fig. 5e shows that the duration of the patient's Map R_{BP} (light red line) does not increase linearly with increasing angles of rotation as in the control subjects reflecting the patient's behavioural deficit for these stimuli. This was confirmed by the absence of a linear trend for the duration of Map R_{BP} as a function of Orientation in the patient ($r^2 = .16$; Fig. 5e). Importantly, our EP-analysis revealed for the earlier phases of BP-processing the same presence and succession of maps (depicted in two shades of grey in Fig. 5a,b) in the patient and the control subjects. This suggests that the patient processed the BP stimuli correctly during the initial perceptual processing stages and presented a selective deficit for a later processing stage, characterised by the relative absence of Map R_{BP}.

In order to localise the generators of Map R_{BP} and as Map R_{BP} was delayed in the patient and absent in most conditions, we applied the linear inverse solution at two different time periods: first, when Map R_{BP} appeared in the control subjects (from 310 to 380 ms) and, second, at the time when it appeared in the patient (in condition MI: from 424 to 460 ms). For the first time period, the results are shown in Fig. 6b and reveal that, in comparison to the left sided activations in the control group, the patient strongly activated both hemispheres and this only in occipital cortex. Thus, no activation was found in the left parietal cortex (location of the patient's brain damage) and left lateral extrastriate cortex (at the temporo-occipital junction). Only during the later time period (424–460 ms; Fig. 6c) did our analysis reveal a weak activation of the left parietal cortex (probably reflecting activation adjacent to the patient's

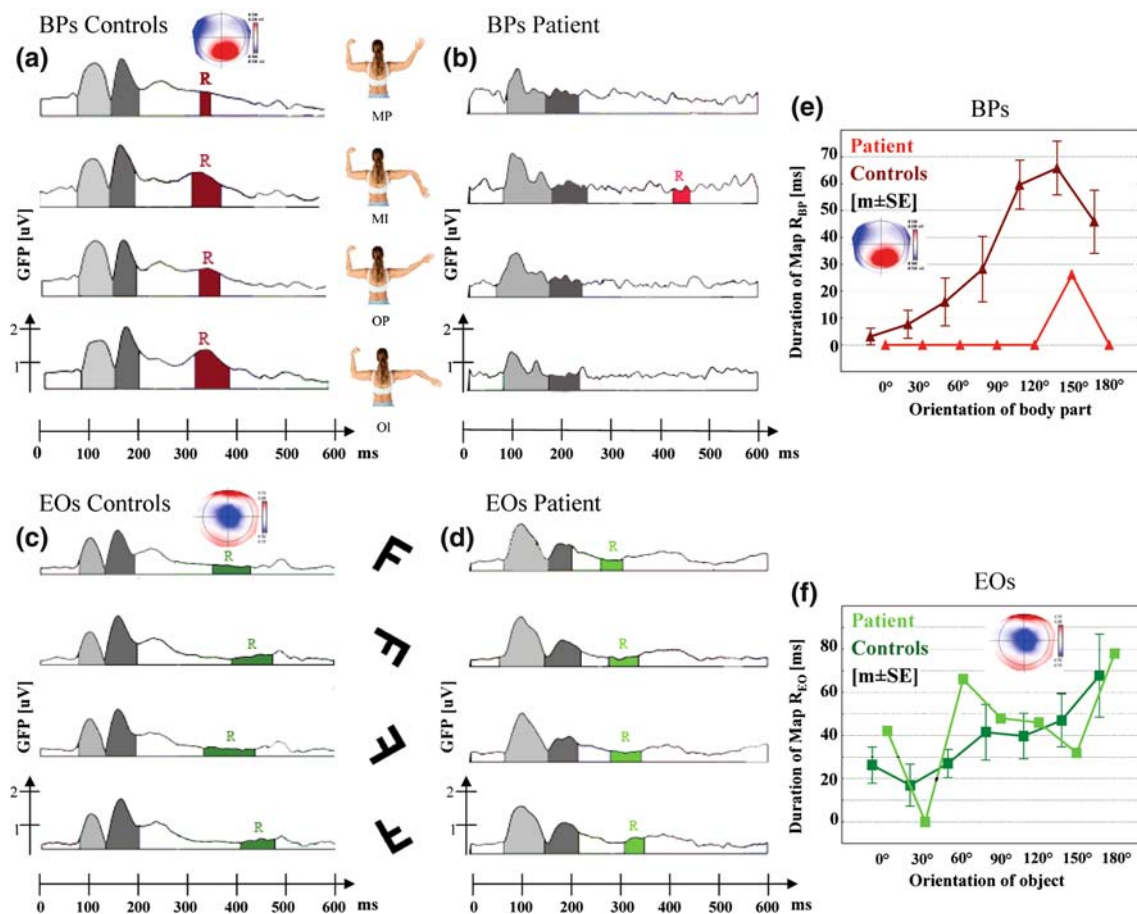


Fig. 5 Evoked potential analysis in control subjects and patient in the BP and EO tasks. The grand mean evoked potentials (EPs) of the control subjects (**a, c**) and the patient (**b, d**), for the four different Conditions (MP, MI, OP, OI) for the BP-task (**a, b**) and the EO-task (**c, d**) are shown. Traces show the global field power (GFP = field strength (in μV)) of the 111-channel ERPs as a function of time after stimulus onset (in milliseconds). Vertical lines under the curves indicate the borders of the segments (functional maps). Maps representing the mental rotation process (R) are represented in red for BPs and in green for EOs. The patient shows the same sequence of maps as control subjects in the early processing (in two shades of grey) of BPs and EOs, which correspond to the P100 and N170. Note,

parietal brain damage) and the left lateral occipito-temporal cortex. To summarise, the patient (1) did not activate left parietal cortex and left occipito-temporal cortex as did the control group and (2) had a more bilateral, and more occipital pattern of activation that was not seen in control subjects during the mental rotation of BPs, although earlier processing stages were normal.

EO-task

Healthy Participants Our analysis of ERPs for EOs in the control subjects showed that 10 maps best explained the four corresponding grand-mean ERP map series. Here again, one particular map (Map R_{EO}) appeared for the

that although these maps are represented in the same shades of grey they are not the same between BPs and EOs. (**e**) Depicts the duration of Map R_{BP} in milliseconds for BPs. The data are plotted separately for the control subjects (dark red line) and the patient (light red line). (**f**) Depicts the duration of Map R_{EO} in milliseconds for EOs as a function of orientation (0°–180°). The data for Map R_{EO} are also plotted separately for the control subjects (dark green line) and the patient (light green line). Note that for the patient, the duration of Map R_{EO} increases with the angle of rotation but that this is not the case for Map R_{BP}. The topographic patterns for Map R_{BP} and Map R_{EO}, plotted with the nasion upward and right ear on the right side, are also shown in **a, e** and **c, f**, respectively

rotated stimuli with its duration increasing linearly with the angular rotation (Fig. 5c, f). Map R_{EO} appeared between 390 and 480 ms after stimulus onset (indicated in dark green in Fig. 5c) in all conditions and was characterised by a longer duration for both conditions with greater rotation angles (conditions MI and OI). A repeated measures ANOVA with Condition and Map duration revealed a main effect of Condition ($F(3, 21) = 4.15, P < .02$), a main effect of Map ($F(1, 7) = 8.22, P < .02$) but no significant Condition \times Map interaction ($F(3, 21) = .27, P = .84$). This was further confirmed by the duration of this map gradually increasing across all seven orientations (dark green line, Fig. 5f) suggesting that this map represented the mental rotation process for EOs (strong linear trend in the

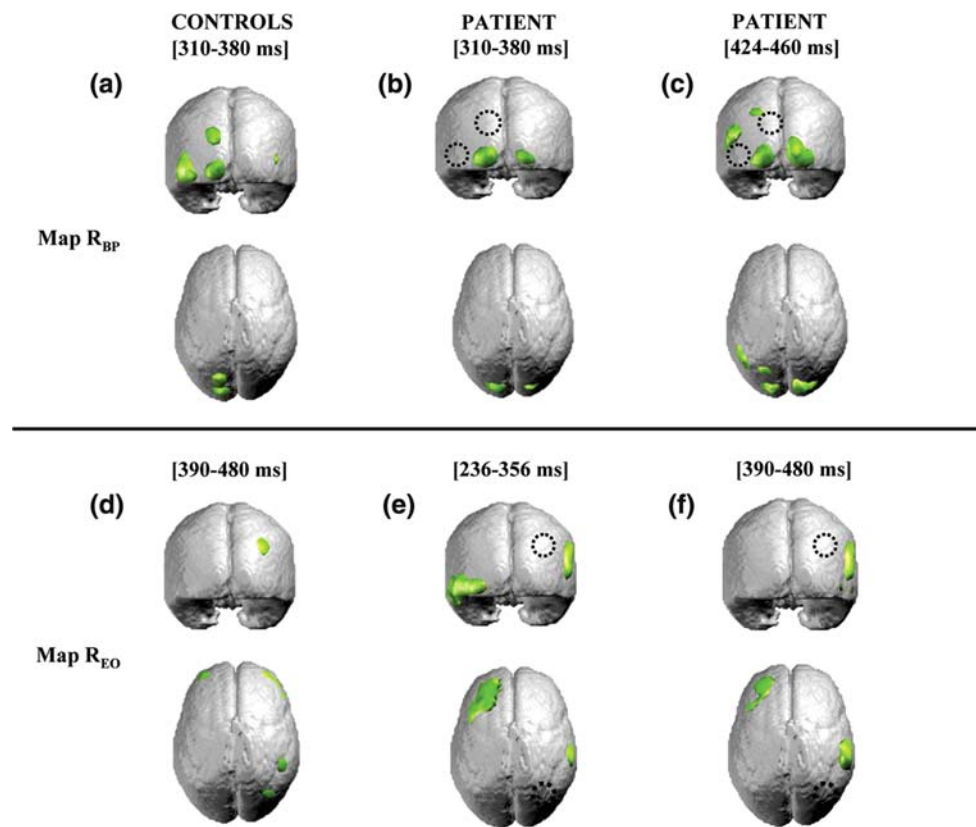


Fig. 6 Source localisation of Map R in the BP and EO tasks. Estimated brain source distributions for Map R in BPs and EOs using a distributed linear source localisation (LAURA; see text). (a–c) Map R_{BP} shows activation in left parietal cortex, left lateral extrastriate cortex (at the temporo-occipital junction), and left occipital cortex for the control subjects (a). For the patient the linear inverse solution was applied at two different periods: when Map R_{BP} appeared in the control subjects (middle; b) and when it appeared in the patient in condition MI (right; c). Both show that the patient most strongly activated the occipital region bilaterally, but not (middle) or only weakly (right) the left parietal cortex. The black circles indicate the areas that were activated in the control subjects, but not by the patient

duration of Map R_{EO} as a function of Orientation in the control subjects; correlation coefficient $r^2 = .82$; analysis of the duration of Map R_{EO} in the individual ERPs of each of the 14 angles). This suggests that the duration of Map R_{EO} reflects the mental rotation function of EOs as the duration of Map R_{BP} reflected the mental rotation function of BPs. The distributed linear inverse solution localised Map R_{EO} to the right parietal cortex (an anterior and a posterior area of activation) and bilaterally in the prefrontal cortex. No activation was observed in the left posterior hemisphere (Fig. 6d).

EO-task

Patient As for Map R_{BP} , we determined whether Map R_{EO} appeared in the patient's ERPs. We found the same succession of maps for the whole evoked potential map

(at the left occipito-temporal and parietal cortex activation). (d–f) Map R_{EO} revealed activations in the right parietal cortex (anterior and posterior areas of activation) and bilaterally in the prefrontal cortex for the control subjects (d). For the EOs the linear inverse solution was also applied at two different periods for the patient: when Map R_{EO} appeared in the patient (middle; e) and when it appeared in the control subjects (right; f). Both reveal activations in the posterior right hemisphere in parietal cortex (anterior area of activation as found in the control subjects) and in the left dorsolateral prefrontal cortex. The earlier time period also shows activation in the left occipito-temporal extrastriate cortex

series. In other words, Map R_{EO} (indicated in light green) was present in the patient for each rotated condition (Fig. 5d). The duration of Map R_{EO} was similar in the patient (mean = 53 ms; range = 42–66 ms) and the control subjects (mean = 85 ± 8 ms) (compare Fig. 5c, d). Although statistical analysis did not find a strong linear trend in the duration of Map R_{EO} as a function of Orientation in the patient ($r^2 = .22$), inspection of Fig. 5f (light green line) shows that the duration of the patient's Map R_{EO} followed a similar trend as control subjects (dark green line) across orientations.

The linear inverse solution applied at the time period where Map R_{EO} appeared in the patient (i.e., from 236 to 356 ms), showed that although bilateral posterior activity was observed (as for the BP task), the strongest activation was found in the posterior right hemisphere, in parietal cortex (overlapping with the anterior activation in control

subjects). Two additional activations were observed in the left hemisphere: in occipito-temporal extrastriate cortex as well as in dorsolateral prefrontal cortex (Fig. 6e). The linear inverse solution applied at the time period where Map R_{EO} appeared in the control subjects (i.e., from 390 to 480 ms) still showed the activation in right parietal cortex and left dorsolateral prefrontal cortex. The activation in left occipito-temporal extrastriate cortex was not present (Fig. 6f).

Discussion

Here we present a patient with left posterior parietal brain damage who developed a selective deficit for the mental transformation of BPs while performing normally for the mental rotation of EOs. Although his scores were in the normal range on paper-and-pencil mental rotation tasks involving both BPs and EOs, our computerised mirror/normal discrimination tasks revealed that he was significantly slower and less correct than control subjects for BPs and EOs. Importantly, whereas control subjects showed a mental rotation function for BPs, this was not the case in the patient. Furthermore, he was significantly faster and more accurate for the mental transformation of EOs than for BPs and his RTs and error rates in the EO-task showed a normal mental rotation function that was comparable (except for generally elevated RTs) with that of control subjects. The patient's error rate for BP was at chance level reflecting his inability perform the task. Yet, he was well able to do the highly similar mental imagery control task, but with other stimuli (EOs) showing that he did not suffer from a conceptual deficit concerning mental imagery or following task instructions. Rather, the orientation of body part stimuli seemed to have been meaningless for him.

The present observation corroborates and extends the previously described deficit for the mental rotation of BPs in a patient with a left fronto-temporo-parietal lesion (Rumiati et al. 2001; Tomasino et al. 2003a). Our findings are also in line with a study by Tomasino et al. (2003b) who demonstrated that patients with right hemisphere damage were impaired in the mental rotation of EOs, but performed normally with BPs, while patients with left hemisphere damage showed the opposite pattern. Sirigu and Duhamel (2001) reported a deficit for the mental rotation of EOs, but not BPs, in a patient with bilateral damage to the inferotemporal cortex. The present study investigated performance in comparable tasks and quantified RTs and accuracy in mental discrimination tasks for EOs and BPs. The behavioural findings in our patient are further corroborated by the observation that his cognitive deficit for mental imagery of BPs is linked to his

contralesional sensori-motor deficit. Indeed, RTs in the BP-task were significantly longer for right arm positions that were contralateral to the patient's brain damage. This finding is reminiscent of results that have reported imagery impairments for movements that patients cannot or have difficulties executing overtly. For instance, Decety and Boisson (1990) found that, when asked to mentally simulate an action, hemiplegic patients showed a significant difference in mental duration times between imagining their paralysed and normal limb. Mental imagery for the paralysed limb was much slower than the healthy one. Sirigu et al. (1995, 1996) also reported patients with difficulties in mentally simulating movements of the hemiparetic hand. These authors suggested that the cerebral mechanisms used in movement preparation and execution are also involved in imagery tasks using BPs. These and our findings suggest that mental imagery for BPs is relatively impaired when participants have to mentally simulate movements with their affected hand/limb as compared to the non-affected one. It appears that the ability to internally simulate BP movements is reduced in the most affected limb. This brings further consistency to the body of evidence that suggests that during mental transformations of bodies or BPs, subjects actually imagine their own body or BP in the position of the stimulus, even though this is not explicitly required by the task. In such situations, a kinaesthetic feeling may occur during the task. The subject experiences the sensations arising as in the actual movement and may therefore evoke a kinaesthetic "image" of it. Such internal movement simulations of parts of the body involve similar neural mechanisms as those activated when planning and executing overt movements (Johnson et al. 2001). More specifically, motor areas have been found to be activated during mental body transformation tasks (Kosslyn et al. 1998; Lang et al. 1996; Wolbert et al. 2003). Thus Jeannerod (1994, 1995) proposed that such motor imagery tasks reflect the conscious experience of an inhibited premotor plan, which would be non-conscious if it were normally executed. Further, it seems that motor imagery is involved in predicting the consequences of an action, thus contributing to movement planning processes (Johnson 2000; Buxbaum et al. 2005). Interestingly, a growing body of evidence suggests a left cerebral dominance for motor planning as shown in studies with participants with hemiparetic cerebral palsy (Mutsaerts et al. 2005, 2007), with left hemispheric stroke (Rushworth et al. 1998), apraxia (Goldenberg 1996; Hermsdörfer et al. 1996; Weiss et al. 2001), and also in participants without brain damage (Schluter et al. 2001). This left cerebral dominance for motor planning could explain the severity of the deficit in mental rotation of BPs found in the present study in a case with left hemispheric brain damage. One could imagine a model similar to that proposed by

Mesulam (1981) in the field of attention (or neglect) in that a lesion to the right cerebral hemisphere would lead to a mental transformation deficit exclusively for contralesional BPs whereas a lesion to the left hemisphere would lead to a bilateral mental transformation deficit affecting ipsilesional and predominantly contralesional BPs. However, before one claims such hemispheric specialization in mental rotation for BPs, more patients with right hemisphere brain damage should be tested with comparable tasks.

Yet, despite being hemiparetic, our patient's weakness predominated distally and he was able to align his right and left arms quite easily with all anatomically possible arm positions that were tested in the BP-task of the present study. Moreover, although the neurological examination revealed deficient proprioception for the right arm, our patient was still able to discriminate correctly between different postures of both his right and left arm. Our patient's mental rotation deficit thus does not seem to be linked to severely deficient movement execution or proprioception per se but probably to a "higher-order" body representation deficit in mental imagery (i.e., depending on the integration of proprioceptive, motor, and visual arm related information) that is—although associated and lateralised with motor and sensory deficits—partially independent of them. This independence of motor and sensory deficits is shown by the absence of a mental rotation function for ipsilesional arm positions that were not affected by sensori-motor deficits at all. Collectively, these behavioural data suggest that the mental imagery for BPs and EOs relies on different functional and anatomical mechanisms and that deficits in mental imagery for BPs are due to left hemispheric brain damage (Rumiati et al. 2001; Tomasino et al. 2003a) centered in the left parietal lobe.

These neuropsychological deficits are corroborated by neuroimaging evidence revealing the absence of brain activation in the left parietal lobe for the mental transformation of BPs in the present patient. Indeed, we have previously shown an activation of the left posterior parietal cortex in mental transformation of BPs (Overney et al. 2005). Most neuroimaging studies that have investigated the mental rotation process used EOs. They usually showed involvement of the right parietal lobe, using various imaging techniques such as PET (Harris et al. 2000), fMRI (Zacks et al. 1999, 2002, 2003b; Podzbenko et al. 2002), EP mapping (Pegna et al. 1997; Yoshino et al. 2000), TMS (Bestmann et al. 2002; Harris and Miniussi 2003), or intracranial electrical cortical stimulation (Zacks et al. 2003a). However, some studies also observed bilateral activation (Tagaris et al. 1996; Alivisatos and Petrides 1997; Carpenter et al. 1999) or even left hemispheric activation (Vingerhoets et al. 2001) during mental rotation of EOs.

Neuroimaging studies on mental transformations of BPs are much less abundant. In a PET study, Bonda et al. (1995) demonstrated that mental rotation of BPs activated three regions in left parietal cortex, the superior parietal lobule, the middle part of the intraparietal sulcus, and the rostral inferior parietal lobule. This parietal activation in proximity to the intraparietal sulcus of the left hemisphere was confirmed in the present EP mapping study in healthy subjects as reported previously (see below; Overney et al. 2005). Further studies have demonstrated the implication of two other areas in visual processing of human bodies and BPs. For instance, the extrastriate body area in extrastriate cortex (at the temporo-occipital junction) has been found to respond stronger to bodies than faces (Downing et al. 2001). In addition, the extrastriate body area not only responds to visual bodies or BPs, but also to proprioceptive signals thus integrating visual and somatosensory body-related information (Astafiev et al. 2004). A number of studies have also implicated cortex at the temporo-parietal junction in the processing of bodies and BPs. In fMRI experiments, Zacks et al. (1999, 2002) showed for the mental transformation of stimuli depicting the entire body that this process relies on both hemispheres, but predominates in the left hemisphere at the junction of temporal, occipital, and parietal lobe. Using a similar task, Blanke and colleagues (Blanke et al. 2005; Arzy et al. 2006) used EP mapping and found that the mental transformation of entire bodies activated the temporo-parietal junction bilaterally with a right hemispheric predominance. In addition, the temporo-parietal junction has also been involved in the integration of multisensory body related information (Leube et al. 2003; Blanke and Arzy 2005). For instance, Leube et al. (2003) have shown that the temporo-parietal junction codes multisensory conflict between visual and proprioceptive information about one's arm position. Blanke et al. (2005) also reported brain activation for BPs at 330–400 ms and thus earlier than the activation that is generally reported for the mental rotation of EOs. This onset of the activation during the mental rotation of EOs has classically been observed at time periods of 450–700 ms in the region of the IPS (Pegna et al. 1997; Harris et al. 2000; Jordan et al. 2001; Gauthier et al. 2002; Podzbenko et al. 2002; Harris and Miniussi 2003) and is also supported by our present results with EOs (Fig. 5).

The present study extends the one by Kosslyn et al. (1998) who showed that EOs led to biparietal activation whereas BPs led to left hemispheric activation in frontal and parietal cortex as well as the insula. In addition, this activation for BPs (which appeared at 310 ms) was shown to increase linearly with increasing degrees of rotation (and increasing RTs) probably reflecting the fact that Map R_{BP} represents the mental transformation process for BPs. Activation during the mental transformation of BPs was

found in the left hemisphere including parietal cortex as suggested by Bonda et al. (1995), in lateral temporo-occipital cortex (Downing et al. 2001; Astafiev et al. 2004), as well as in the occipital cortex. With respect to EOs, we also showed a specific activation (Map R_{EO}) the duration of which increased linearly with increasing degrees of rotation (and increasing RTs). Importantly, Map R_{EO} appeared later than Map R_{BP} and yielded activation in right parietal cortex. The present patient data and previous data in healthy subjects and directly comparable tasks thus suggest that the mental rotation of EOs relies more on right parietal structures, whereas the mental transformation of BPs relies more on left parietal and temporo-occipital structures. However, as mentioned earlier, some previous neuroimaging studies on EOs have found bilateral or even left hemisphere activation during mental rotation tasks. A possible explanation for some of the variability in these previous studies might be related to the fact that they used different paradigms, such as two-stimuli- or single stimulus presentations (Harris et al. 2000; Vingerhoets et al. 2001). The majority of studies that used the classical Shepard and Metzler stimuli found bilateral activations, which could be due to eye movements and shifts of attention (which are known to activate parietal and frontal areas bilaterally; Corbetta et al. 1993; Anderson et al. 1994) between the two stimuli, whereas the majority of studies using single-stimulus presentation seem to suggest a right hemisphere dominance for mental rotation of EOs (Harris et al. 2000; Harris and Miniussi 2003). In the present study, a single-stimulus paradigm was used for both BPs and EOs providing evidence that both types of stimuli rely on different neural mechanisms in different hemispheres.

This was further suggested by the patient's brain activation patterns. Concordant with his behavioural results in the BP-task due to damage to left parietal cortex, the patient's EPs were not characterised by normal brain activations during Map R_{BP} (during the period that Map R_{BP} was found in healthy controls) as found in the control subjects. Moreover, his abnormal brain activation was restricted to Map R_{BP} since earlier EP components during the BP-task were normally present. Thus, the patient did not show the brain activation that our analysis selectively related to the mental transformation of BPs. We also found that his brain activation during mental transformation of BPs remained for much longer time periods in occipital cortex and was also characterised by a more bilateral and thus stronger right hemispheric brain activation pattern. We argue that the patient, due to his damage to the left parietal cortex, was not able to generate the normal brain activation patterns at the normal moment in time during the mental transformation of BPs as observed in control subjects. Indeed, during the time period when Map R_{BP} was found in the control subjects (310–380 ms), our patient did not show

any activity originating from the left or right intraparietal sulcus or the left occipito-temporal region. Instead, he showed bilateral posterior activation in the occipital lobes. Even during a later period (424–460 ms), when the patient did show some weak activation resembling Map R_{BP} , this was still localised bilaterally and in occipital cortex, with weak activations in perilesional parietal and temporo-occipital cortex. These data show that the patient was selectively engaging different neural mechanisms in the left and right hemisphere than control subjects when attempting to perform the BP-task.

Yet, a cautionary remark seems mandatory since we used a younger control group for EP analysis and cannot therefore exclude that the mental transformation process is not performed in the same way in old and younger adults. Some studies have compared the brain networks involved in mental transformations in adults and children (Funk et al. 2005; Kucian et al. 2007) but to our knowledge, none have made a comparison between young adults and elderly people.

The situation was different in the EO-task where the patient showed similar behaviour and brain activation patterns with similar timing and localisation as the control subjects. Importantly, the patient and control subjects showed a mental rotation map (Map R_{EO}), the duration of which increased linearly with the angle of rotation. This Map R_{EO} was localised in the right parietal cortex as shown in controls and in previous studies (Harris et al. 2000; Podzbenko et al. 2002), although the patient also activated additional areas in the left hemisphere, which were not observed in the control subjects.

Conclusion

Our data show that different neural mechanisms are implicated in mental transformation of EOs and BPs. We present neuropsychological evidence for this dissociation by showing a selective impairment in mental transformation of BPs (human arm positions) in a patient with brain damage to the left parietal cortex. The patient's deficit was characterised by increased reaction times, absence of a mental rotation function, and a predominant deficit for the mental transformation of contralesional BPs. Selective neuroimaging evidence corroborated the patient's neuropsychological impairment as he did not show brain activation in left parietal cortex as found for mental transformation of BPs in healthy participants. Importantly, his performance with EOs did not differ with respect to healthy participants in terms of either behavioural results or the patterns of brain activation during mental rotation of EOs. These data collectively suggest that mental imagery for BPs relies on different behavioural and neural

mechanisms than for EOs and identify a module in left parietal cortex that is necessary for the processing of human BPs.

Acknowledgements This research was supported by an iMURS Scholarship from Macquarie University to L. Overney. We thank Irina Harris for her constructive comments on a previous version of the manuscript and Christoph Michel for allowing us to use the infrastructure of the Functional Brain Mapping Laboratory (Geneva, Switzerland). We thank Denis Brunet for providing Cartool and Martine Lamon for her help in collecting part of the data.

References

- Alivisatos B, Petrides M (1997) Functional activation of the human brain during mental rotation. *Neuropsychologia* 35:111–118
- Anderson TJ, Jenkins IH, Brooks DJ, Hawken MB, Frackowiak RS, Kennard C (1994) Cortical control of saccades and fixation in man. A PET study. *Brain* 117:1073–1084
- Arzy S, Thut G, Mohr C, Michel CM, Blanke O (2006) Neural basis of embodiment: distinct contributions of temporoparietal junction and extrastriate body area. *J Neurosci* 26:8074–8081
- Astafiev SV, Stanley CM, Shulman GL, Corbetta M (2004) Extrastriate body area in human occipital cortex responds to the performance of motor actions. *Nat Neurosci* 7:542–548
- Benton AL, Sivan A, Hamsher K, Varney NR, Spreen O (1994) Facial recognition: Stimulus and multiple choice pictures: Contributions to neuropsychological assessment. Oxford University Press, New York, pp 35–52
- Bestmann S, Thilo KV, Sauner D, Siebner HR, Rothwell JC (2002) Parietal magnetic stimulation delays visuomotor mental rotation at increased processing demands. *Neuroimage* 17:1512–1520
- Blanke O, Arzy S (2005) The out-of-body experience: disturbed self-processing at the temporo-parietal junction. *Neuroscientist* 11:16–24
- Blanke O, Mohr C, Michel CM, Pascual-Leone A, Brugger P, Seeck M, Landis T, Thut G (2005) Linking out-of-body experience and self processing to mental own body imagery at the temporoparietal junction. *J Neurosci* 25:550–557
- Bonda E, Petrides M, Frey S, Evans A (1995) Neural correlates of mental transformations of the body-in-space. *Proc Nat Acad Sci* 92:11180–11184
- Buxbaum LJ, Johnson-Frey SH, Bartlett-Williams M (2005) Deficient internal models for planning hand-object interactions in apraxia. *Neuropsychologia* 43:917–929
- Carpenter PA, Just MA, Keller TA, Eddy W, Thulborn K (1999) Graded functional activation in the visuospatial system with the amount of task demand. *J Cogn Neurosci* 11:9–24
- Cooper LA, Shepard RN (1973) The time required to prepare for a rotated stimulus. *Mem Cogn* 1:246–250
- Cooper LA, Shepard RN (1975) Mental transformations in the identification of left and right hands. *J Exp Psychol: Hum Perc Perf* 104:48–56
- Corballis MC (1997) Mental rotation and the right hemisphere. *Brain Lang* 57:100–121
- Corballis MC, Sergent J (1988) Imagery in a commissurotomed patient. *Neuropsychologia* 25:13–26
- Corbetta M, Miezin FM, Shulman GL, Petersen SE (1993) A PET study of visuospatial attention. *J Neurosci* 13:1202–1226
- Culver CM (1969) Test of right-left discrimination. *Percept Mot Skills* 2:863–867
- Decety J, Boisson D (1990) Effect of brain and spinal cord injuries on motor imagery. *Eur Arch Psychiatry Clin Neurosci* 240:39–43
- Ditunno PL, Mann VA (1990) Right hemisphere specialisation for mental rotation in normals and brain damaged subjects. *Cortex* 26:177–188
- Downing PE, Jiang Y, Shuman M, Kanwisher N (2001) A cortical area selective for visual processing of the human body. *Science* 293:2470–2473
- Farah MJ, Hammond KM (1988) Mental rotation and orientation-invariant object recognition: dissociable processes. *Cognition* 29:29–46
- Funk M, Brugger P, Wilkening F (2005) Motor processes in children's imagery: the case of mental rotation of hands. *Dev Sci* 8:402–408
- Gauthier I, Hayward WG, Tarr MJ, Anderson AW, Skudlarski P, Gore JC (2002) BOLD activity during mental rotation and viewpoint-dependent object recognition. *Neuron* 34:161–171
- Goldenberg G (1996) Defective imitation of hand and finger postures in patients with damage in the left or right hemispheres. *J Neurol Neurosurg Psychiatry* 61:176–180
- Grave de Peralta R, Gonzalez SL, Lantz G, Michel CM, Landis T (2001) Noninvasive localization of electromagnetic epileptic activity. Method descriptions and simulations. *Brain Topogr* 14:131–137
- Grave de Peralta R, Menendez R, Murray MM, Michel CM, Martuzzi R, Gonzalez Andino SL (2004) Electrical neuroimaging based on biophysical constraints. *NeuroImage* 21:527–539
- Harris IM, Miniussi C (2003) Parietal lobe contribution to mental rotation demonstrated with rTMS. *J Cogn Neurosci* 15:315–323
- Harris IM, Egan GF, Sonkkila C, Tochon-Danguy HJ, Paxinos G, Watson JD (2000) Selective right parietal lobe activation during mental rotation: a parametric PET study. *Brain* 123:65–73
- Hauert C-A, Sevino O (1996) Test de rotation mentale. Document de l'Université de Genève
- Hermesdörfer J, Mai N, Spatt J, Marquardt C, Veltkamp R, Goldenberg G (1996) Kinematic analysis of movement imitation in apraxia. *Brain* 119:1575–1586
- Itier RJ, Taylor MJ (2004) Source analysis of the N170 to faces and objects. *NeuroReport* 15:1261–1265
- Jeannerod M (1994) The representing brain: neural correlates of motor intention and imagery. *Behav Brain Sci* 17:187–245
- Jeannerod M (1995) Mental imagery in the motor context. *Neuropsychologia* 33:1419–1432
- Johnson SH (2000) Thinking ahead: the case for motor imagery in prospective judgments of prehension. *Cognition* 74:33–70
- Johnson SH, Corballis PM, Gazzaniga MS (2001) Within grasp but out of reach: evidence for a double dissociation between imagined hand and arm movements in the left cerebral hemisphere. *Neuropsychologia* 39:36–50
- Jolicoeur P (1985) The time to name disoriented natural objects. *Mem Cogn* 13:289–303
- Jordan K, Heinze HJ, Lutz K, Kanowski M, Jancke L (2001) Cortical activations during the mental rotation of different visual objects. *NeuroImage* 13:143–152
- Kosslyn SM (1994) *Image and brain*. MIT Press, Cambridge
- Kosslyn SM, Digirolamo GJ, Thompson WL, Alpert NM (1998) Mental rotation of objects versus hands: neural mechanisms revealed by positron emission tomography. *Psychophysiology* 35:151–161
- Kucian K, von Aster M, Loenneker T, Dietrich T, Mast FW, Martin E (2007) Brain activation during mental rotation in school children and adults. *J Neural Transm* 114:675–686
- Lang W, Cheyne D, Hollinger P, Gerschlager W, Lindinger G (1996) Electric and magnetic fields of the brain accompanying internal simulation of movement. *Cogn Brain Res* 3:125–129
- Lehmann D, Ozaki H, Pal I (1986) Averaging of spectral power and phase via vector diagram best fits without reference electrode or

- reference channel. *Electroencephalogr Clin Neurophysiol* 64:350–363
- Leube DT, Knoblich G, Erb M, Grodd W, Bartels M, Kircher TTT (2003) The neural correlates of perceiving one's own movements. *NeuroImage* 20:2084–2090
- Mesulam MM (1981) A cortical network for directed attention and unilateral neglect. *Ann Neurol* 10:309–325
- Michel CM, Thut G, Morand S, Khateb A, Pegna A, Grave de Peralta R, Gonzalez S, Seeck M, Landis T (2001) Electric source imaging of human brain functions. *Brain Res Rev* 36:108–118
- Michel CM, Murray MM, Lantz G, Gonzalez S, Spinelli L, Grave de Peralta R (2004) EEG source imaging. *Clin Neurophysiol* 115:2195–2222
- Murray MM, Michel CM, Grave de Peralta R, Ortigue S, Brunet D, Gonzalez Andino S, Schnider A (2004) Rapid discrimination of visual and multisensory memories revealed by electrical neuroimaging. *NeuroImage* 21:125–135
- Murray MM, Brunet D, Michel CM (2008) Topographic ERP analyses: a step-by-step tutorial review. *Brain Topogr* 20:249–264
- Mutsaerts M, Steenbergen B, Bekkering H (2005) Anticipatory planning of movement sequences in hemiparetic cerebral palsy. *Mot Cont* 9:435–454
- Mutsaerts M, Steenbergen B, Bekkering H (2007) Impaired motor imagery in right hemiparetic cerebral palsy. *Neuropsychologia* 45:853–859
- Oldfield RC (1971) The assessment and analysis of handedness: the Edinburgh inventory. *Neuropsychologia* 9:97–113
- Overney LS, Michel CM, Harris IM, Pegna AJ (2005) Cerebral processes in mental transformations of body parts: recognition prior to rotation. *Cogn Brain Res* 25:722–734
- Parsons LM (1987) Imagined spatial transformations of one's hands and feet. *Cogn Psychol* 19:178–241
- Pascual-Marqui RD, Michel CM, Lehmann D (1995) Segmentation of brain electrical activity into microstates: model estimation and validation. *IEEE Trans Biomed Eng* 42:658–665
- Pegna AJ, Khateb A, Spinelli L, Seeck M, Landis T, Michel CM (1997) Unravelling the cerebral dynamics of mental imagery. *Hum Brain Map* 5:410–421
- Petit LS, Harris IM (2005) Anatomical limitations in mental transformations of body parts. *Vis Cogn* 12:737–758
- Petit LS, Pegna AJ, Harris IM, Michel CM (2006) Automatic motor cortex activation for natural as compared to awkward grips of a manipulable object. *Exp Brain Res* 168:120–130
- Podzebenko K, Egan GF, Watson JDG (2002) Widespread dorsal stream activation during a parametric mental rotation task revealed with functional magnetic resonance imaging. *Neuroimage* 15:547–558
- Rumiati RI, Tomasino B, Vorano L, Umiltà C, De Luca G (2001) Selective deficit of imagining finger configurations. *Cortex* 37:730–733
- Rushworth MFS, Nixon PD, Wade S, Renowden S, Passingham RE (1998) The left hemisphere and the selection of learned actions. *Neuropsychologia* 36:11–24
- Schluter ND, Krams M, Rushworth MFS, Passingham RE (2001) Cerebral dominance for action in the human brain: the selection of actions. *Neuropsychologia* 39:105–113
- Schnider A (2003) Spontaneous confabulation and the adaptation of thought to ongoing reality. *Nat Rev Neurosci* 4:662–671
- Sekiyama K (1982) Kinesthetic aspects of mental representations in the identification of left and right hands. *Percept Psychophys* 32:89–95
- Shepard RN (1984) Ecological constraints on internal representation: resonant kinematics of perceiving, imagining, thinking and dreaming. *Psychol Rev* 91:417–447
- Shepard RN, Cooper LA (1982) *Mental images and their transformations*. MIT Press, Cambridge, London
- Shepard RN, Metzler J (1971) Mental rotation of three-dimensional objects. *Science* 171:701–703
- Sirigu A, Duhamel JR (2001) Motor and visual imagery as two complementary but neurally dissociable mental processes. *J Cogn Neurosci* 13:910–919
- Sirigu A, Cohen L, Duhamel JR, Pillon B, Dubois B, Agid Y, Pierrot-Deseilligny C (1995) Congruent unilateral impairments for real and imagined hand movements. *NeuroReport* 6:997–1001
- Sirigu A, Duhamel JR, Cohen L, Pillon B, Dubois B, Agid Y (1996) The mental representation of hand movements after parietal cortex damage. *Science* 273:1564–1568
- Tagaris GA, Kim SG, Strupp JP, Andersen P, Ugurbil K, Georgopoulos AP (1996) Quantitative relations between parietal activation and performance in mental rotation. *NeuroReport* 7:773–776
- Tomasino B, Rumiati RI, Umiltà CA (2003a) Selective deficit of motor imagery as tapped by a left-right decision of visually presented hands. *Brain Cogn* 53:376–380
- Tomasino B, Tormaldo A, Rumiati RI (2003b) Dissociation between the mental rotation of visual images and motor images in unilateral brain-damaged patients. *Brain Cogn* 51:368–371
- Vingerhoets G, Santens P, Van Laere K, Lahorte P, Dierckx RA, De Reuck J (2001) Regional brain activity during different paradigms of mental rotation in healthy volunteers: a positron emission tomography study. *Neuroimage* 13:381–391
- Warrington EK, James M (1991) *Visual object and space perception test*. Thames Valley Test Company, Bury St. Edmunds (UK)
- Weiss PH, Dohle C, Binkofski F, Schnitzler A, Freund HJ, Hefter H (2001) Motor impairment in patients with parietal lesions: disturbances of meaningless arm movement sequences. *Neuropsychologia* 39:397–405
- Winer BJ, Brown DR, Michels KM (1991) *Statistical principles in experimental design*. McGraw-Hill, New York
- Wolbert T, Weiller C, Büchel C (2003) Contralateral coding of imagined body parts in the superior parietal lobe. *Cereb Cortex* 13:392–399
- Yoshino A, Inoue M, Suzuki A (2000) A topographic electrophysiologic study of mental rotation. *Cogn Brain Res* 9:121–124
- Zacks JM, Rypma B, Gabrieli JDE, Tversky B, Glover GH (1999) Imagined transformations of bodies: an fMRI investigation. *Neuropsychologia* 37:1029–1040
- Zacks JM, Ollinger JM, Sheridan MA, Tversky B (2002) A parametric study of mental spatial transformations of bodies. *Neuroimage* 16:857–872
- Zacks JM, Gilliam F, Ojemann JG (2003a) Selective disturbance of mental rotation by cortical stimulation. *Neuropsychologia* 41:1659–1667
- Zacks JM, Vettel JM, Michelon P (2003b) Imagined viewer and object rotations dissociated with event-related fMRI. *J Cogn Neurosci* 15:1002–1018